



PATIENT PRESENTING CLINICAL SIGNS

Logan Davis

History: Grade 3/6 heart murmur. Weight loss.

SPECIES ECHOCARDIOGRAM FINDINGS

Feline

2D, m-mode, color flow and doppler imaging is available. The left ventricular wall is asymmetric and irregular with regions of mild hypertrophy. Extensive visualization is limited. There is a mildly hyperechoic endocardium consistent with fibrosis. The papillary muscles are mildly hypertrophied. The left atrium is normal in size. The right atrium is normal in size. Mild SAM is suspected with mild MR. No TR. Blood flow through the RVOT is normal. The blood flow through the LVOT is normal on doppler; however, an intermittent LVOTO is suspected on color flow and 2D imaging. No pleural or pericardial effusion seen. No obvious cardiac tumors.

BREED

DSH

SEX CARDIAC CHART

Male Neutered

AGE

13 years

WEIGHT

8lbs

INTERPRETED BY

Maggie Machen
Lamy, DVM, DACVIM
(Cardiology)

IMAGING PERFORMED BY

Rebekah Jakum, CVT
ARDMS/RVT

HOSPITAL NAME

Cherryville Animal
Hospital

REFERRING VET

Dr. Myers

INVOICE

26390

DATE

9/15/22

FELINE CARDIAC PARAMETERS	BODY WEIGHT (kg)	HR (BPM)	IVSd (cm) (Moise, Pipers)	LVIDd (cm) (Moise, Pipers)	LVWd (cm) (Moise, Pipers)	FS (%)	EF (%)
NORMAL PARAMETER	-----	150-240	0.35-0.55	<2 (mean 1.5)	3.5-0.55	35-67	80-100
PATIENT		156	0.54	1.25	0.64	67	95
FELINE CARDIAC PARAMETERS	LA/AO (Boon)	LA/AO HEART BASE (Swe) (Abbott)	LA 2D short axis Base view (cm) (Abbott)		LVOT VEL (m/s)	RVOT VEL (m/s)	E max (m/s)
NORMAL	<1.5	<1.3	<1.2		<1.6	<1.3	<0.9
PATIENT	NM	1.4	1.3		1.6	1.0	NM

**Note: All measurements based upon multi-modal images and methods. An average value is reported.*
Adapted from June Boon, Veterinary Echocardiography, 1998
Abbott J & MacLean H JVIM 2006;20: 111-119, Moise et al. Am J Vet Res 47:1476, 1986. Pipers et al. Am J Vet Res 40:882, 1979.

INTERPRETATION OF THE FINDINGS & FURTHER RECOMMENDATIONS

The primary abnormality identified is minimal LV hypertrophy, which may be indicative of early hypertrophic disease or may simply represent a normal variant. The LA is normal which would indicate clinical stability. Serial echocardiography will be necessary to determine progression and clinical significance. Additionally, the murmur is due to a mild LVOT obstruction with secondary MR, which appears intermittent and does not warrant therapy. Baseline BP and T4 are strongly recommended with monitoring every 6 months. No additional issues are identified.

Anesthetic risk is considered mild, however judicious IV fluid rates are advised to avoid fluid overload. Additionally, drugs that stimulate heart rate should be avoided unless clinically necessary (glycopyrrolate, atropine). Avoid vasodilators as this may worsen the obstruction. A reasonable protocol includes opioid/benzodiazepine premedication, propofol induction, isoflurane maintenance. Additionally, steroids should be used with caution on older cats, as even a 'normal' geriatric heart can develop evidence of intolerance and fluid retention.



PATIENT

Logan Davis

SPECIES

Feline

BREED

DSH

SEX

Male Neutered

AGE

13 years

WEIGHT

8lbs

INTERPRETED BY

Maggie Machen
Lamy, DVM, DACVIM
(Cardiology)

**IMAGING
PERFORMED BY**

Rebekah Jakum, CVT
ARDMS/RVT

HOSPITAL NAME

Cherryville Animal
Hospital

REFERRING VET

Dr. Myers

INVOICE

26390

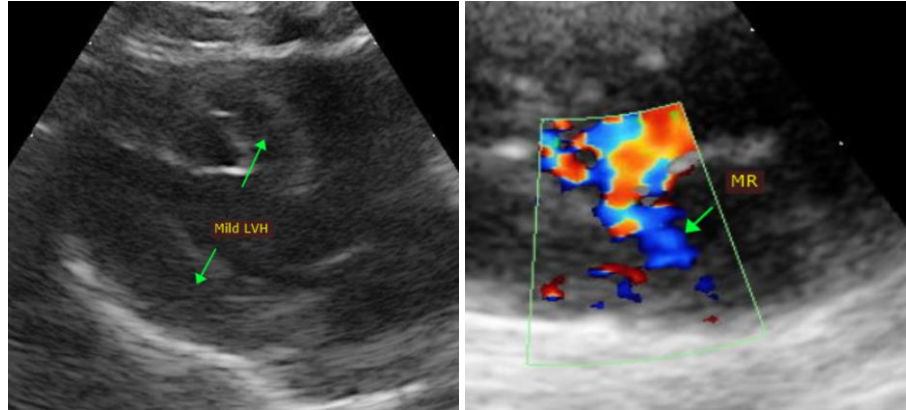
DATE

9/15/22

Monitor for any development of clinical signs, including labored breathing or signs of a blood clot (paralysis, neurologic change). Prognosis is guarded prior to assessing for progression.

A recheck echocardiogram is recommended in 6-12 months to screen for any evidence of progression.

IMAGES



The information and recommendations provided are based on the images presented by the referring veterinarian. No evaluation can be communicated regarding pathology that was not visible in the image/video clips provided.

Thank you for this referral. This report was generated using transcription software, and minor dictation errors may be present. If the clinical or image interpretation does not parallel your findings or if I can be of any further assistance, please contact me.

Maggie Machen Lamy, DVM
Diplomate of the American College of Veterinary Internal Medicine (Cardiology)